

Short-term consumption of Gelam honey reduces triglyceride level

¹Samat, S., ¹Mohd Nor, N., ²Hussein, F. N., ¹Eshak, Z. and ^{1,2*}Ismail, W. I. W.

¹Faculty of Pharmacy, Universiti Teknologi MARA, Puncak Alam Campus, 42300 Bandar Puncak Alam, Selangor, Malaysia

²Faculty of Veterinary Medicine, Universiti Putra Malaysia, 43400 Serdang, Selangor, Malaysia

³School of Fundamental Science, Universiti Malaysia Terengganu, 21030 Kuala Nerus, Terengganu, Malaysia

Article history

Received: 18 July 2016

Received in revised form:

17 August 2016

Accepted: 19 August 2016

Abstract

The study was carried out to evaluate short-term administration of Gelam honey. A single oral administration of the honey at a dose of 5000 mg/kg body weight on male Sprague Dawley rats (test group) for 14 days did not produce any signs of toxicity, behavioral changes, mortality, changes on gross appearance or histopathological changes of internal organs. The examinations of signs, animal behavior and health monitoring showed no abnormalities in the test group as compared to the rats unfed with the honey (control group). The test group had progressive increased both body weight and in the meal pattern analysis. However, triglycerides level was found significantly decreased in the test group. It suggested that the honey might have a decent effect in controlling the blood triglyceride level. Polyphenol contents in the honey may play the role to reduce the triglyceride level. Biochemical test for aspartate aminotransferase (AST), alanine transaminase (ALT), urea, creatinine, cholesterol and glucose of rats in the test group were in the normal range compared to the control. There were no significant changes in the absolute and relative organ weight between the two groups. As a conclusion, tested dose of Gelam honey is safe and has medical potential. Meanwhile, lethal dose (LD50) of the honey was found to be greater than 5000 mg/kg body weight. Long period of Gelam honey consumption should be conducted to observe and confirm those effects.

Keywords

Acute toxicity study

Animal study

Malaysian honey

Short-term administration

Triglyceride level

© All Rights Reserved

Introduction

Honey is sweet in taste, golden in color and concentrated liquid in natural condition. It is obtained from liquid nectar of many plants and is a food source for honey bees (Bogdanov *et al.*, 2012). Honey is classified from clear to dark color due to its flavors, mineral contents, quality and floral source (Uthurry *et al.*, 2011). Physical characteristic of honey is according to its viscous liquids and able to be identified by its flavor, appearance, color, crystallization and presence of pollen grains in honey sediment (Bogdanov *et al.*, 2012).

Gelam honey is one of many types of monofloral Malaysian honey, which is produced by honey bee from *Melaleuca* species plant (Hussein *et al.*, 2011). It has high components of polyphenols and non-phenol content activities compared to other local honeys in Malaysia (Piljac-Žegarac, 2009). Thus, it possesses both antioxidant and polyphenols agents, which are important to prevent occurrence of chronic diseases, infections and can improve enzyme activities to the optimal level in the body (Alvarez-Suarez *et al.*,

2010).

Honey is claimed does not give any adverse effect in daily intake; because honey is a natural product that has biological and chemical bioequivalent toward human body needs. However, only few studies have to date taken into cognizance of the possible toxicity effects of Gelam honey even though progressive researches have been conducted on the honey. In addition, toxicity study is one of the requirements towards to clinical studies in order to observe other possible medicinal value of honey systematically. Therefore, this study was undertaken to observe the toxicity effects of acute administrations of Gelam honey at the highest doses 5000 mg/kg body weight on male Sprague Dawley rats for 14 days according to the Organisation for Economic Co-operation and Development (OECD).

Materials and Methods

Sample collection

Gelam honey was collected from Gelam forest, Terengganu, Malaysia. The sample was irradiated

*Corresponding author.

Email: wantryani@gmail.com

with 25 kGy gamma irradiation using radioactive sources cobalt 60 (model JS8900) at Malaysian Nuclear Agency (MINT), Selangor, Malaysia (Hussein *et al.*, 2011). The irradiated honey was then kept in 4°C, away from direct sunlight in amber bottles.

Experimental animals

The experimental protocol was approved by the Research Committee on The Ethical Use of Animal (UiTM Care) Reference No. 05/2012. Ten apparently healthy male Sprague Dawley rats were obtained from Laboratory Facilities of Animal Management (LAFAM), University Teknologi MARA (UiTM), Puncak Alam, Selangor, Malaysia. At the commencement of its dose, each animal was eight weeks old and its weight was between 180 to 220 g (OECD/OCDE, 2001). The rats were housed at one rat per cage and maintained in standard environmental conditions under an ambient temperature of $25 \pm 2^\circ\text{C}$ and 40 - 65% relative humidity, with a 12-h light/dark cycle. They were fed with certified rodent food (Rodent Diet Specialty Feeds, Glen Forrest Australia) and drinking water was available ad libitum. The animals were acclimatized for five days prior to the commencement of the study and labeled appropriately. A completely randomized design was used in dividing the rats into two groups that consisted five male in each group i.e. control rats were orally administered with distilled water and rat chow ad libitum (control group) and tested group where rats were fed with Gelam honey (5000 mg/kg body weight) (test group).

Acute toxicity study

Acute oral toxicity test was performed to observe short-term administration of honey according to the guidelines of OECD for testing of chemicals, TG 423 with slightly modifications (OECD/OCDE, 2001). It measures adverse effects occurred following oral administration of a single dose of a substance, or multiple doses given within 24 hours such as general behavior, respiratory pattern, cardiovascular signs, motor activities, reflexes and changes in skin and fur texture. For the test group, fixed dose of Gelam honey, 5000 mg/kg body weight of male Sprague Dawley rats were orally given once whereas the control group was administered with distilled water. The doses given were calculated according to animal's body weight on the week of specified treatment. The median lethal oral dose (LD50), which is a statistically derived single dose of a substance that can be expected to cause death in 50% of animals when administered by the oral route, was

determined. The LD50 value is expressed in terms of weight of test substance per unit weight of test animal (mg/kg)(OECD/OCDE, 2001). Dosing for this study was initiated at 5000 mg/kg because there was no estimate of the substance's lethality available so far. Thus, the maximal dose was used as suggested by the OECD. Meanwhile, mortality and the clinical signs of toxicity were observed at 30 minutes, 1, 2 and 4 hours and thereafter once a day for the next 14 days (Samat *et al.*, 2014).

Body weight and meal pattern analysis

The body weight of each rat was recorded daily and the differences of the body weight were noted (OECD/OCDE, 2001). The food efficiency was calculated at the end of study as the quantity of food (in g) consumed by each rat by subtracting the weight of uneaten food from initial weight of food (Vinicus *et al.*, 2006). Then, the total number of kilocalories that each rats consumed was determined by multiplying the caloric content of 1 g of each diet by the total quantity eaten (Mohd Saleh *et al.*, 2012).

Measurement of blood chemical parameters

The nonheparinized blood was subjected to biochemical tests using an Auto Analyser ILAB 300 Plus Clinical Chemistry Analyser, Milano Italy. The blood was allowed to coagulate prior to centrifuged. Then, the serum was separated to analyze glucose, urea, creatinine, aspartate aminotransferase (AST), alanine transaminase (ALT), glucose, triglycerides and cholesterol.

Histology evaluation

On day 14 of the dosing period, all the animals were euthanized by diethyl ether. The organs such as heart, liver, spleen, kidneys and lungs were weighed and relative organ weights (ROW) were calculated (Mohd Saleh *et al.*, 2012). The ROW of each animal was then calculated as follows:

$$\text{Relative organ weight} = \{(\text{Absolute organ weight (g)} / \text{Body weight of rat on sacrifice day (g)}) \times 100\}$$

For histology evaluation, the internal organs were fixed in 10% neutral buffered formalin, trimmed and a 5 μ thickness of tissue sections were stained with hematoxylin and eosin for histopathological investigation.

Statistical analysis

Results were expressed as mean \pm standard average mean (SEM). Statistical significance was determined by one-way analysis of variance

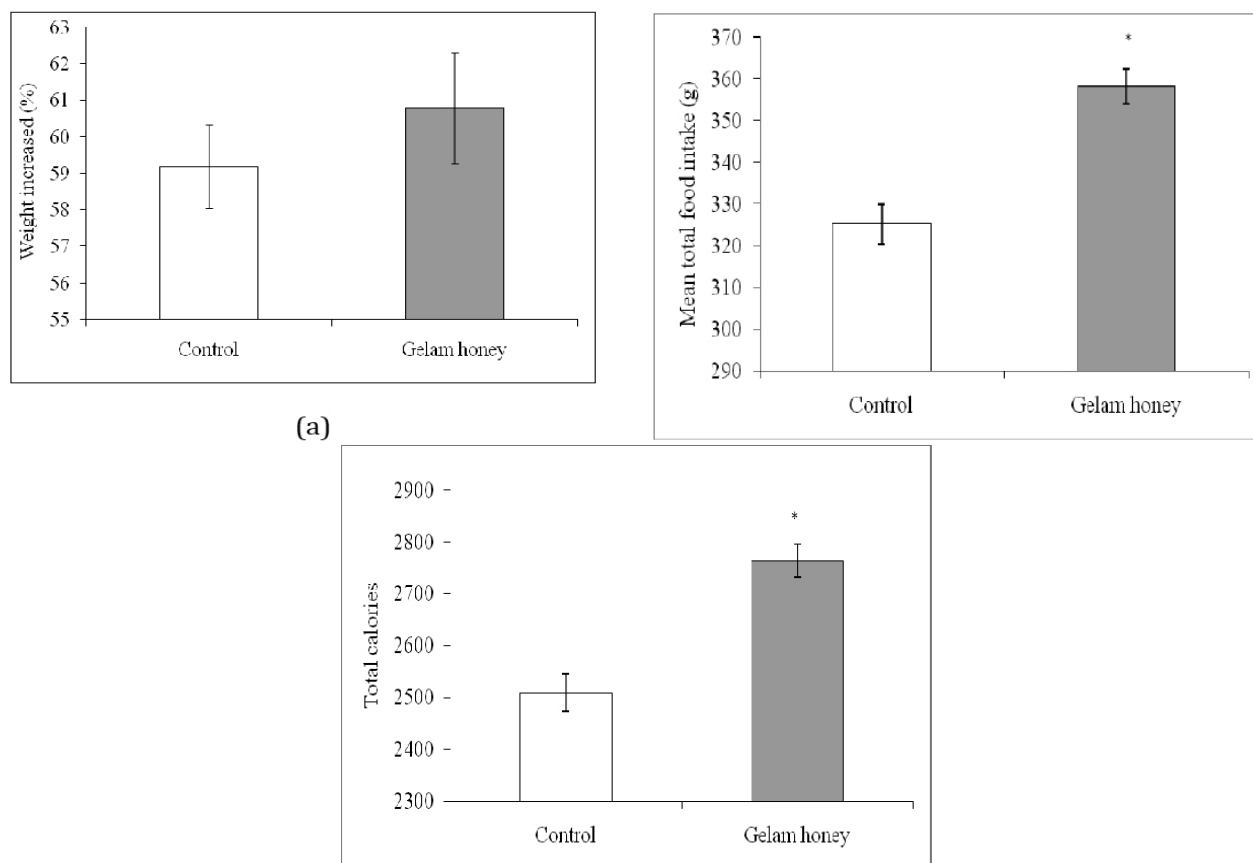


Figure 1. Effects of oral administration of 5000 mg/kg Gelam honey on body weight (a), mean total food intake (b), and calories of male Sprague Dawley rats. The values are expressed as mean \pm SEM (n=5); * significant different ($p < 0.05$) versus control

Results

Acute toxicity studies

At the dose level tested given once orally i.e. Gelam honey at 5000 mg/kg body weight of Sprague Dawley rats, no morbidity and mortality observed in the test group after 14 days of the experiment. No apparent differences in physical activities or other behaviors throughout the study period in the test and control groups. There were no changes in the nature stool, urine and eye color of all the animals. Moreover, there was no diarrhea, salivation, convulsion, sleep or coma which are signs associated with oral toxicity and there was also no significant loss of fur and skin lesions (OECD/OCDE, 2001). No death rats were observed after fed with Gelam honey at 5000 mg/kg body weight. Hence, LD50 values were estimated to be above of the concentration.

Body weight and meal pattern

There was gradual increased but not significantly different in body weight of rats fed with the honey (60.78%) and in the control group (59.20%) (Figure 1(a)). Total food intake for the test group was significantly increased compared to the control group

(Figure 1(b)). During 14 days of diet regimens, cumulative food intake of rats among both group was slightly different in mass. Mean total food intake for the test and control groups were 358.18 g and 325.25 g respectively. In sums, total calories consumed from the mean total food intake for rats fed with Gelam honey was 2763.79 calories compared to the control group was 2509.62 calories (Figure 1(c)).

Biochemical analysis

Overall, results of biochemical analysis for the test group showed an increased but still in normal range for all tests (ALT, urea, creatinine, cholesterol and glucose) except for AST showed significantly increased compared to the control (Table 1). However, for triglyceride level, rats fed with Gelam honey showed the significantly decreased (0.84 mmol/L) compared to the control (2.04 mmol/L).

Relative organ weight

Relative organ weight for the liver, kidney, spleen, heart and lung were not affected by Gelam honey supplementation (Table 2). In addition, gross necropsy findings did not reveal changes in any of the organs examined.

Table 1. Biochemical changes of male Sprague Dawley rats after 14 days of acute oral administration of Gelam honey (5000 mg/kg). Results are reported as mean \pm SEM (n=5); ALT: alanine aminotransferase; AST: aspartate aminotransferase, * significant different ($p < 0.05$) versus control.

Parameter	Control group	Test group	Reference values (iLAB, 2012)
ALT (U/L)	52.90 \pm 3.23	55.26 \pm 3.52	52.70 \pm 4.20
AST (U/L)	103.56 \pm 2.36	123.96 \pm 2.34*	108.20 \pm 12.10
Urea (mg/dL)	38.60 \pm 1.73	40.50 \pm 0.73	41.10 \pm 9.11
Creatinine (μ mol/L)	70.82 \pm 2.56	68.98 \pm 1.98	70.90 \pm 8.20
Cholesterol (mmol/L)	1.49 \pm 0.19	1.27 \pm 0.13	1.52 \pm 0.19
Triglycerides (mmol/L)	1.33 \pm 0.12	0.92 \pm 0.14	1.33 \pm 0.51
Glucose (mmol/L)	4.26 \pm 0.32	4.40 \pm 0.19	4.30 \pm 0.39

(ANOVA) followed with Tukey's test post-hoc using SPSS software version 18.0 (SPSS, Chicago IL, USA). Values with a confidence level of $p \leq 0.05$ were considered as significant.

Table 2. Effects of Gelam honey and control on relative organ weights (ROW) of male Sprague Dawley rats. Results are reported as mean \pm SEM (n=5); * significant different ($p < 0.05$) versus

Organ	Control group	Test group (Gelam honey)
Heart	0.202 \pm 0.03	0.208 \pm 0.03
Spleen	0.149 \pm 0.01	0.178 \pm 0.03*
Lung	0.288 \pm 0.03	0.275 \pm 0.04
Kidney	0.530 \pm 0.02	0.522 \pm 0.04
Liver	2.930 \pm 0.21	2.810 \pm 0.25

Histology evaluation

For the histology investigation, no pathological changes were observed in the liver of animals in the control group (Figure 2(a)) and the test group (Figure 2(b)), which showed normal lobular architecture with central vein and radiating hepatic cords. The macroscopic observation of the organs did also not present any significant morphological or hemorrhagic changes due to the administration of Gelam honey at 5000 mg/kg body weight. Other organs including spleen, lung, kidney and heart showed no sign of pathological changes compared with the corresponding organs of the control.

Discussion

Honey has been used for medicinal purposes in many cultures since the ancient times (Enette Larson-Meyer *et al.*, 2010; Ajibola *et al.*, 2012). It is one of the oldest and most enduring-substance used in wound management. Scientific evidences for their efficacy are widely studied but systemic safety studies are still lacking. Therefore, it is essential to evaluate the toxicity of honey in animal model to ensure its safety and may further it in clinical studies.

The study was designed to assess the acute toxicity induced by Gelam honey after administrated orally at the maximum dose 5000 mg/kg body weight of Sprague Dawley rats based on OECD guidelines. According to the OECD 423 test guidelines (Jonsson

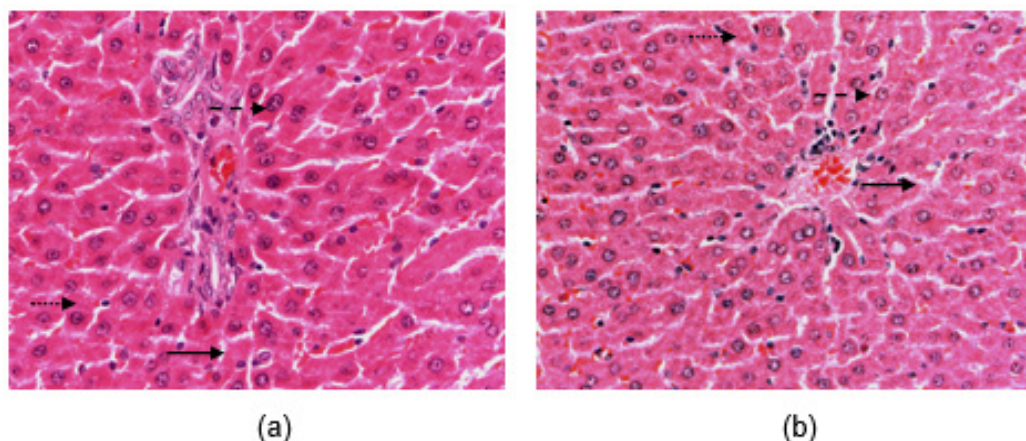


Figure 2. Photomicrograph of the liver of a control Sprague dawley group (a), and rat orally administered with Gelam honey dose of 5000 mg/kg body weight for 14 days (b). Hepatocyte (—→), normal sinusoid (- - ->), kupffer cells (.....>) (HE staining x 400).

et al., 2012), the 5000 mg/kg body weight doses were chosen because the dosage is safe, applicable and appropriate to evaluate safety of some substances.

The acute oral toxicity study is performed to observe a short period consumption of substances. The present study was conducted by administering the single dose of Gelam honey for 14 days using male Sprague Dawley rats only. Male rat is an appropriate model for the short course study since female rat is frequently affected by its hormonal levels (Mark *et al.*, 2005). There were no any detectable physical toxicological symptoms like mortality, morbidity, loss of fur, diarrhea, convulsion, salivation, fatigue, sleep, coma or aggression. The aforementioned signs are indicators of interference of toxicants with the passage of electrical impulses down the axon.

The increment of body weight for the test group considered as normal when compared to the control group. Then, the increasing patterns of food intake for the test group paralleled with calories consumed. Although, biochemical test for hepatic function (ALT and AST) were slightly higher, gross pathological examination of the Gelam honey groups (Figure 4(b)) did not reveal any abnormalities, presence of lesions or changes in the color of the internal organs compared to the control (Figure 2(a)).

Intriguingly, triglycerides levels in rats fed with the honey were significantly decreased compared to the control. It indicates Gelam honey consumption might not be having lipogenic effects and reveals its potential in controlling triglycerides level. The major compound contributes to the effects are polyphenols since the compounds were reported available in the honey (Alvarez-Suarez *et al.*, 2010; Hussein *et al.*, 2011). Polyphenols were widely reported to control triglyceride level, consequently provide benefits to the cardiovascular system (Khurana *et al.*, 2013).

There were no significant differences in internal organ weight. Organ weight measurement is important to access general toxicity because any changes in organ weight is a sensitive indicator for toxicity (Norazmir and Ayub, 2010). ROW results of liver were slightly decreased compared to control but not significant (Mark *et al.*, 2005; Mark *et al.*, 2012). ROW of liver was measured, as it is the target organ of the most toxicants. Normally, toxicants enter the body via the gastrointestinal tract and are carried by the hepatic portal vein to the liver for elimination (Srivinas *et al.*, 2010).

The findings imply that short-term exposure to high concentration of Gelam honey does not produce health hazards in the male Sprague Dawley rats. The slightly changes observed in the body weight and body weight gain may have resulted from physiological changes in rats such as metabolism, food and water intake. At the same time, Gelam honey consumption may have medical benefit in controlling triglyceride level in the bloodstream.

Conclusion

Gelam honey at the highest concentration level tested (5000 mg/kg body weight of male Sprague Dawley rats) did not cause any mortality, physiological or behavioral changes in rats. The results suggest that the Gelam honey does not demonstrate acute toxicity effect in rats even at the maximal concentration based on the OECD guidelines. It may have good effects in fatty acid metabolism via controlling triglycerides level in the bloodstream through its polyphenol compounds. Further studies to assess a long-term safety of the Gelam honey and its effect on the lipid metabolism are intensively carrying out in laboratory.

Acknowledgements

The author would like to acknowledge the Faculty of Pharmacy, UiTM Puncak Alam for the great facilities throughout the research project. The appreciation also goes to Research Management Institute (RMI), UiTM for their kind assistances. This research has been supported by Research Entity Initiative (REI) grant 600-RMI/ST/REI 5/3 Fst (9/2013).

References

- Ajibola, A.W., Chamunorwa, J.P. and Erlwanger, K.H. 2012. Long-term dietary supplementation with natural honey does not predispose growing male rats to metabolic syndrome. *BMC Proceedings* 6 (Suppl. 3): P3.
- Alvarez-Suarez, J., Tulipani, S., Romandini, S., Bertoli, E., Battino, M., Fawcett, K.A. and Aarland, A. 2010. Contribution of honey in nutrition and human health: a review. *Mediterranean Journal of Nutrition and Metabolism* 3(1): 15-23.
- Bogdanov, S., Jurendic, T., Sieber, R., Gallmann, P., Jasmin, R.F. and Fawcett, K.A. 2012. Honey as nutrient and functional food. *Journal of the American College of Nutrition* 40(13): 1-37.
- Enette Larson-Meyer, D., Kentz, R.D., Willis, S., Lindsey, M., Willis, Kathleen, J.A., Ann, M. Hart., Ashley, B.B. and Brenda, M.A. 2010. Effect of honey versus sucrose on appetite, appetite-regulating hormones, and postmeal thermogenesis. *Journal of the American College of Nutrition* 29(5): 482-493.
- Hussein, S.Z., Kamaruddin, M.Y., Makpol, S. and Yusof, Y.A.M. 2011. Antioxidant capacities and total phenolic contents increase with gamma irradiation in two types of Malaysian honey. *Molecules* 16: 6378-6395.
- Jonsson, M., Jestoi, M., Nathanail, A.V., Kokkonen, U.M., Anttila, M., Koivisto, P. and Peltonen, K. 2012. Application of OECD Guideline 423 in assessing the acute oral toxicity of moniliformin. *Food and Chemical Toxicology* 53: 27-32.
- Khurana, S., Venkataraman, K., Hollingsworth, A., Piche, M. and Tai, T. C. 2013. Polyphenols: Benefits to the cardiovascular system in health and in aging. *Nutrients* 5: 3779-3827.
- Mark, A.S., Karla, A.S. and Wilson, R.P. 2012. *The Laboratory Rabbit, Guinea Pig, Hamster, and Other Rodents*. Oxford: Elsevier.
- Mark, A.S., Steven, H.W. and Craig, L.F. 2005. *The Laboratory Rat (American College of Laboratory Animal Medicine)*. San Deigo: Elsevier
- Mohd Saleh, A.K., Ghazali, A.R., Yahya, N.A., Wasiman, M.I. and Ismail, Z. 2012. Acute toxicity study of standardized *Mitragyna speciosa* Korth aqueous extract in Sprague Dawley rats. *Journal of Plant Studies* 1(2): 120-129.
- Norazmir, M.N. and Ayub, M.Y. 2010. Beneficial lipid lowering effects of pink guava puree in high fat diet induced obese rats. *Malaysian Jurnal Nutrition* 16(1): 171-185.
- OECD/OCDE. 2001. Acute oral toxicity-acute toxic class method. OECD Guideline for the Testing of Chemicals (423): 1-14.
- Piljac-Žegarac, J. 2009. Antioxidant properties and phenolic content of different floral origin honeys. *Journal of ApiProduct and ApiMedical Science* 1(2): 43-50.
- Srivinas, A., Surekha, P.A., Kishore, A.S., Srinivasan, M., Balakrishna Murthy, P. and Neelakanta Reddy, P. 2010. Toxicity profile of Abharak and Tamar Bhamas in different vehicles. *Journal of Herbal Medicine and Toxicology* 4(2): 189-196.
- Samat, S., Md Nor, N. A., Hussein, F. N. and Ismail, W. I. W. 2014. Effects of Gelam and Acacia honey acute administration on some biochemical parameters of Sprague Dawley rats. *BMC Complementary and Alternative Medicine* 14(146): 1-8.
- Uthurry, C.A., Hevia, D., Gomez-Cordoves, C., Saito, H., Pannu, N. and Waas, J.R. 2011. Role of honey polyphenols in health. *Journal of ApiProduct and ApiMedical Science* 3(4): 141-159.
- Vinicus, V.D., Eduardo, N.T. and Trindade, M.R.M. 2006. Experimental model to induce obesity in rats. *Acta Cirurgica Brasileira* 21(6): 425-429.